

Landmarks in the Historical Development of Fluorescein Angiography

Patrick J. Same, M.Ed., CRA

Davis Duehr Eye Associates, Madison, WI

Introduction

In 1961 two medical students from Indiana, H.R. Novotny and D.L. Alvis, authored a paper which described retinal angiography techniques still in use today.¹ The utilization of a fundus camera equipped with an exciter filter, barrier filter, and electronic flash to sequentially document the retinal blood flow following a sodium fluorescein injection was outlined in their landmark article. The complete story behind the implementation of this procedure began many years prior to this seminal report, however. The fluorescein angiography procedure is a culmination of the evolution of retinal imaging intersecting with the application of sodium fluorescein to ophthalmology.

This paper reviews published landmarks in the historical development of fluorescein angiography by examining the evolution of retinal photography, the historical use of dyes to view the retina, and important work contemporaneous with Novotny and Alvis. It traces the history of the fluorescein angiography procedure through selected quotes from the publications of significant contributors. A list of resources is included. The reader is encouraged to further explore the historical record.

Beginnings

The basic building blocks from which fluorescein angiography evolved include anatomical drawings of the retina and the use of fluorescein dye to view ophthalmic phenomena.

Fundus photography was developed in pursuit of an accurate and specific graphic representation of the retina. Medical illustration has a long history of depicting the eye: the ancient Greeks made anatomical drawings of the eye (Fig 1).² A landmark in the realistic graphic representation of the retina was an 1854 publication by Van Trigt (Fig 2).³ It is here that the story of modern fundus photography begins. From Duke-Elder:

"The frontispiece to this volume is interesting. It is a photographic representation of the first coloured printed illustration of the fundus of the eye which appeared in the thesis of Adrian Christopher Van Trigt (1825-64), Dissertatio Ophthalmologica Inauguralis de Speculo Oculi in 1853... " Duke-Elder, 1967

Jackman, Webster and Bedell note early attempts at retinal photography on anesthetized animals.^{4,5} The

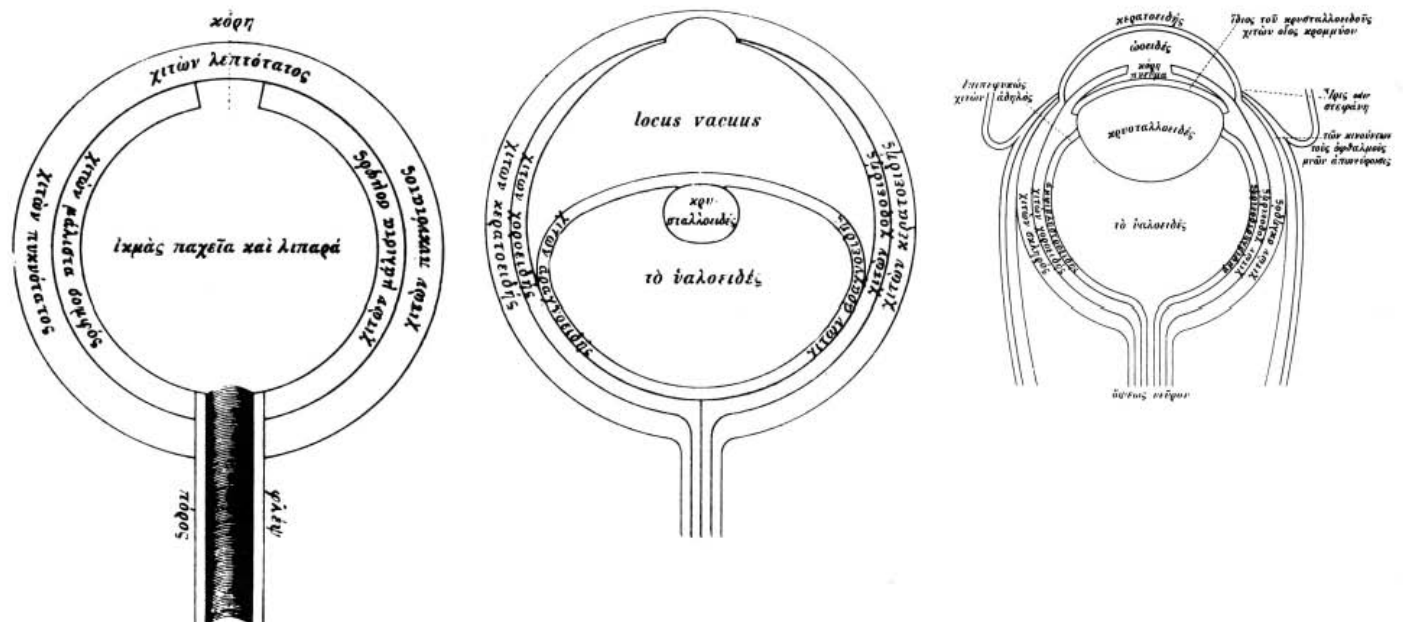


Figure 1A: An eye as illustrated by Democritus in approximately 400 BC. Note the simple, two layer construction and the hollow tube' which connects the eye to the brain. (B) Drawings by Celsus 400 years later included a lens, the anterior chamber, and the vitreous. (C) Galen's eye, from about 150 AD, was much closer to reality, even if his theories were not. (reproduced from Duke-Elder, 1961).

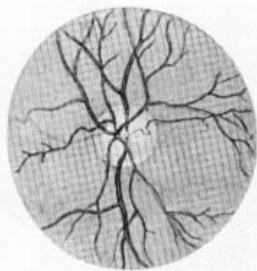


Figure 2: This realistic illustration was originally drawn in color by Van Trigt in 1853. (reproduced from Duke-Elder, 1967).

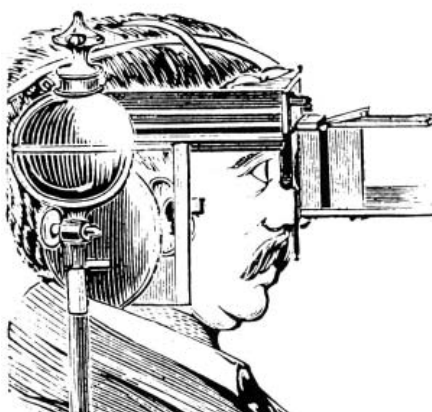


Figure 3: The first published human fundus photograph involved this apparatus, an alco-carbon burner, and a 2½ minute exposure. (reproduced from Mann, 1970).

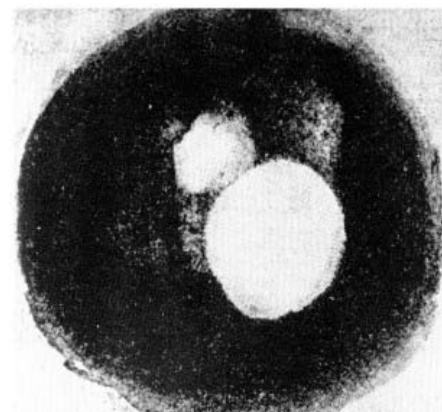


Figure 4: With some imagination, you may recognize the small top white area as the optic disc, and the lower, larger light area as an artifact. Blood vessels are unable to be defined. (reproduced from Mann, 1970).

first published account of in-vivo human retinal photography is by Jackman and Webster in 1886.⁴ They describe the use of an ophthalmoscopic mirror (a curved mirror with a centrally located hole) in conjunction with a two inch microscope objective (Fig 3). An alco-carbon light source provided illumination during the 2½ minute exposure. From their paper:

"After considerable practice, and numerous experiments, we have at last succeeded in obtaining a very fair photograph of the blind spot and a few larger blood vessels of the living human retina." Jackman and Webster, 1886

As important as these early attempts were, it should be noted that the images were quite blurry (Fig 4). Improvements in instrumentation and technique were needed before high quality fundus photography was to become routine.

Adolf Baeyer, a 1905 Nobel Laureate in chemistry, described methods for producing a number of new organic dyes—including sodium fluorescein—in 1871.6 Ten years later, fluorescein dye was utilized by Ehrlich to examine the flow of the aqueous humor.⁷ This is the first published use of sodium fluorescein in ophthalmology; sodium fluorescein has since become an important ophthalmic tool. Ehrlich describes his methods:

"I proceeded to inject 2cc of fluorescein, and when the yellow absorbed—this happened in a few minutes—I saw an effect nearby. After ¼ to ½ minutes I could see a spot near the pupil border, soon the spot encircled the pupil and I saw an intense green fluorescent color which diffused throughout the anterior chamber within 2-3 minutes." Ehrlich, 1881

Colored Dyes and the Eye

Ehrlich's investigation of fluorescein in the eye was followed in 1910 by Burke who examined the choroid

and retina after the administration of fluorescein dye in coffee.⁸ In 1930, Kikai viewed the retina with filtered light in an attempt to more clearly view injected dye.⁹ It was not until 1939 that the path of dye in the retinal blood vessels was described.¹⁰ While reading this next excerpt, imagine, if you will, how the history of fluorescein angiography may have been changed if Sorsby had a specific interest in photographing the retina, or if his experiments had been carried out with a different patient population.

"With these dyes whilst effective staining of the brain could be obtained in the intact animal, staining of the fundus was, as with the pure basic dyes, of the most transient character. The retinal vessels could be seen carrying a coloured blood stream for about two minutes, but the colouration of the fundus amounted to little more than a transient flushing. . .

The experimental observation that the damaged retina retained the colour suggested the possibility that the diseased retina in man might behave similarly." Sorsby, 1939

The use of fluorescein dye in circulation studies of the intestine and skin were summarized by Lange and Boyd in 1942.¹¹ Their technique included the rapid injection of 2-4cc of 5% sodium fluorescein in the antecubital vein. Using a purple light for excitation, they observed the effect of fluorescein dye on multiple tissues. Except for the lack of specifics describing ophthalmic imaging, their paper describes, in very general terms, modern fluorescein angiography:

"If a definite section of tissue containing a small artery and vein is observed with the aid of a low power microscope after intravenous injection, one readily can watch the stain enter the artery, pass the capillaries, stain the surrounding tissue and return through the vein." Lange and Boyd, 1942

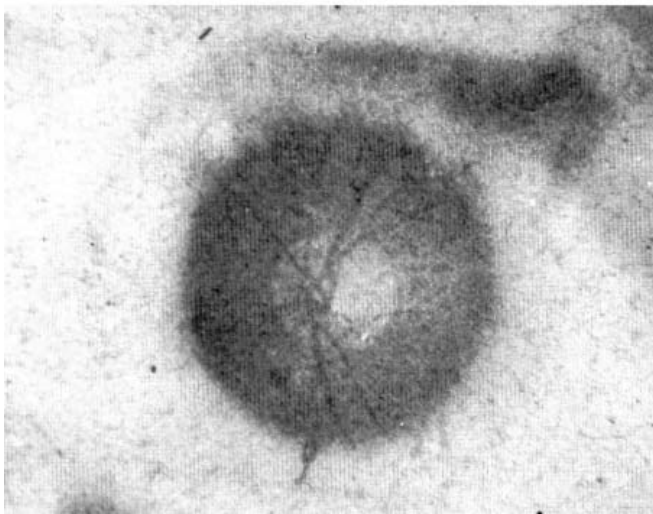
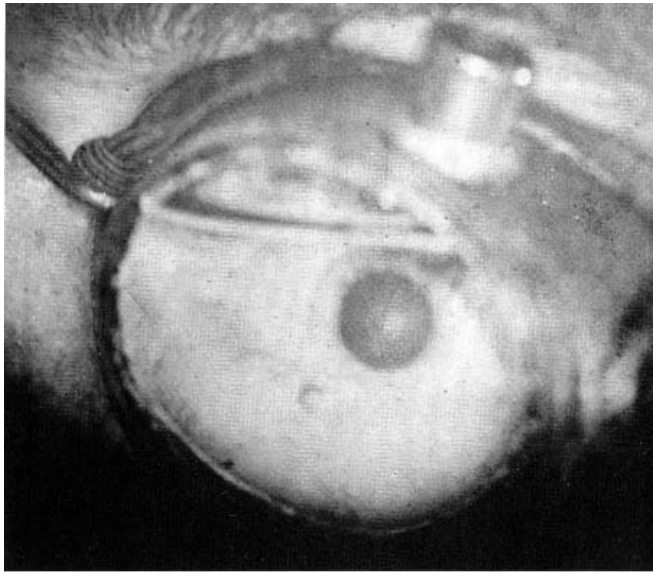


Figure 5 : Gerloff's retinal photograph lacks magnification, but is much clearer than earlier efforts. **(B)** Detail (reproduced from Gerloff, 1891).

Fundus Photography Refined

Rapid progress in fundus photography was made in the years just after Jackman and Webster's fuzzy fundus photographs were published. Howe and Barr both made progress toward better quality, as evidenced in the next three quotes:12,13

"The photograph to which I venture to call attention is here presented. It will be seen that the disc is perfectly distinct, even the shading of the different parts is well defined. Moreover, the vessels are so clearly shown over at least a third of the fundus that the arteries can be distinguished from the veins... .

For while it must be admitted that the results here presented are not entirely satisfactory, on the other hand this is, as far as I can learn, the first time that any photographs of the interior of the eye have been produced in which the details were even recognizable, and as such, they at least give promise of results of great practical value in the future." Howe, 1887

The next quote is taken from the discussion which directly followed Howe's paper:

"Letter A Carbutt's dry plate is used with ten minutes exposure to an ordinary gas light, giving an unretouched and unremagnified negative ... "Discussion of above paper, 1887

Barr contributed thusly:

"Up to the present time, so far as I am able to learn, attempts to photograph the interior of the human eye have not yielded very encouraging results. In the Philadelphia Photographer, of June 5, 1886, Drs. Jackman and Webster, of Coggestall, Essex, England, give results of their experiments. They succeeded in showing the end of the optic nerve and an indistinct outline of a part of one or two large vessels... .

I began experimenting to obtain a photograph of the interior of the human eye, and the results are better than others I have seen, showing the optic nerve and vessels quite well... .

The lens in the camera has a focus of only three inches, and this I think is important, for it makes a very bright image, and consequently a very short exposure—six to ten seconds—is sufficient..... Barr 1887


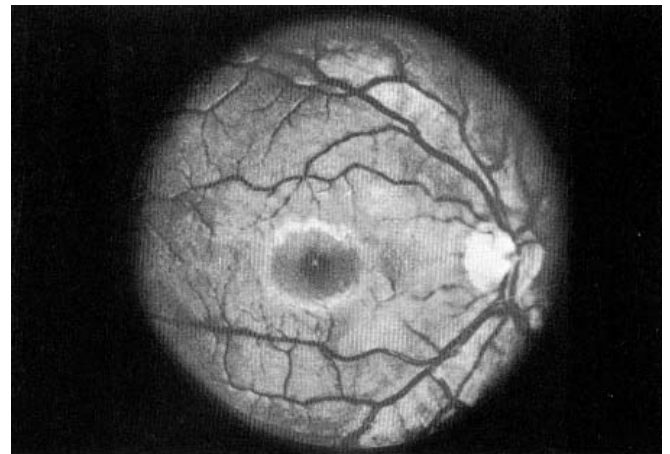


Figure 6A: This fine photograph of a normal eye was published in Dimmer and Pillat's 1927 atlas. **(B)** Dimmer's fundus camera. (reproduced from Dimmer and Pillat, 1927).

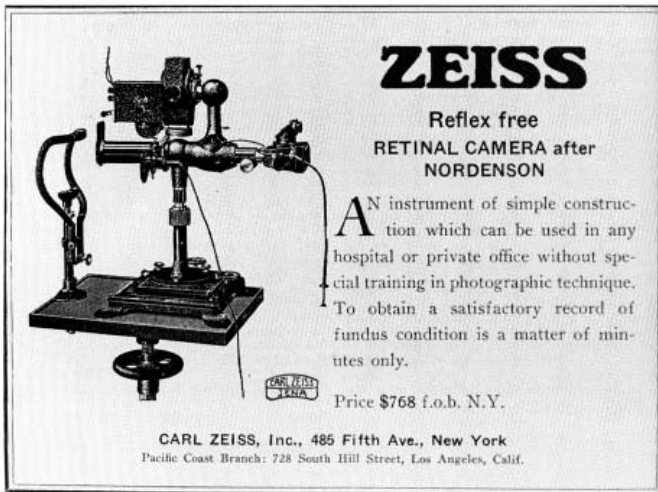


Figure 7: An advertisement for the Zeiss fundus camera from 1932. Fundus cameras have changed dramatically in the last 50 years. Advertising copy has not. (reproduced from American Journal of Ophthalmology, 1932).

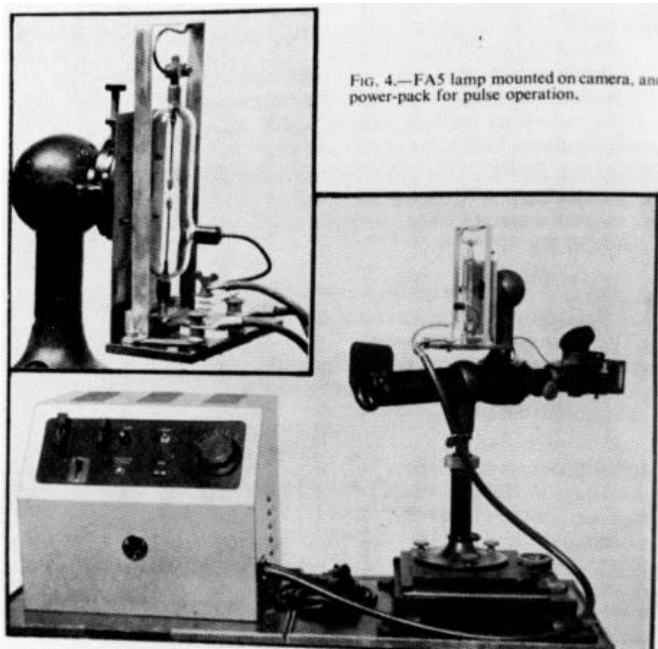


Figure 8: Hansell and Beeson modified a fundus camera to include an electronic flash tube. (reproduced from Hansell and Beeson, 1953).

In 1891, Gerhoff used flash powder to illuminate a low magnification fundus photograph (Fig 5).¹⁴ Bedell cites Bagneries (1887) and Gerhoff (1891) as pioneers in fundus photography, and notes that in 1899 Dimmer "electrified the Ninth International Congress with his marvelous pictures."⁵ In 1907, Dimmer published the first fundus photography atlas.¹⁵ His high quality black and white photographs were obtained using a cumbersome apparatus and carbon arc illumination (Fig 6).

Modern fundus camera design began in 1851 when Helmholtz introduced the direct ophthalmoscope.¹⁶ Its design was improved upon by Thorner in 1899 and

Gullstrand in 1910.^{17,18} Nordenson introduced a camera based on Gullstrand's principles in 1925.¹⁹ The Carl Zeiss Company marketed Nordenson's design as the first commercially available fundus camera in 1926 (Fig 7).²⁰ This camera had a 10° field of view and required a 1/2 second exposure with color film.²¹

Bedell published a stereo atlas of fundus photographs in 1929.²² In June of 1935, Bedell delivered the Chairman's Address at the 86th Annual Session of the American Medical Association.⁶ He described the current state of ophthalmic photography with this paragraph:

"Direct color photography has attracted attention and some excellent pictures have been presented, but because of the expense and the difficulty of reproduction, it is not as yet popular. Eventually, drawings will be supplanted and even the most skillful artist will be forced to admit the superiority of photographs. For several years I have been taking colored photographs." Bedell, 1935

Limitations in clinical use of fundus photography in the 30's and 40's can be directly attributed to the difficulty in obtaining quality images. Slow film speeds and long shutter speeds were the rule with the then current carbon arc illumination system. (Although Hartinger described a modification of the fundus cam-

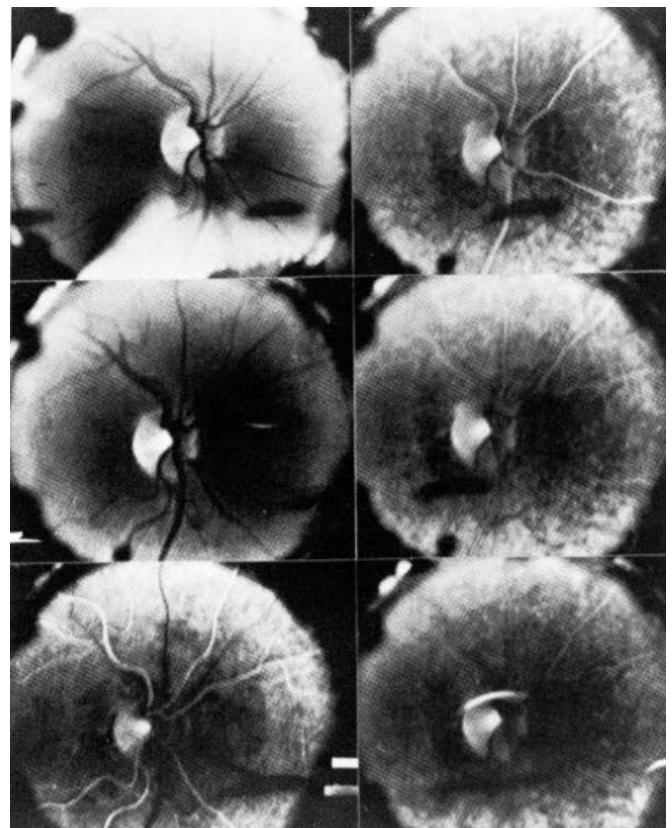


Figure 9: The first modern fluorescein angiogram was taken by Dr. Novotny of Dr. Alvis in 1959. Note the use of match sticks to signify print sequence. (reproduced from Alvis and Julian, 1982).

era by the addition of an electrical lamp, carbon arc fundus cameras continued to be used through the forties.^{23,24} A bright, instantaneous light source was needed for high quality, routine fundus photography.

External eye photographs taken with a 'lightning illumination process' were shown by Cohn and Bois in 1888.²⁵ In 1946, Edgerton developed the electronic flash tube, and in 1949 Rizzutti introduced its use to ophthalmology.^{26,27} Electronic flash was adapted to the fundus camera in 1953 in both Britain and the United States (Fig 8):^{24,28}

"The application of a new compact xenon arc lamp (FA5) to retinal photography in colour is described. The circuit required for pulse operation of the lamp is given and some modifications of the Zeiss-Nordenson retinal camera are mentioned... .

By these means standard and comparable records of the fundus oculi may be obtained on Kodachrome colour film at exposures of $\frac{1}{25}$ sec." Hansell and Beeson, 1953

"By using again the ring of light just within the pupil to illuminate the retina, and photographing directly through the center of the pupil, one can obtain pictures which are reflex-free. Because the flash exposure of the tube is of the order of 0.0001 second, the problems of blinking and of the movements of the eye being photographed are eliminated. The use of the flash-tube technique also is less fatiguing and annoying to the patient." Ogle and Rucker, 1953

By the early 1950's, fluorescein dye had been observed flowing through the retina, filters had been used to enhance the visualization of the retina filled with dye, and flash-adapted fundus cameras were a reality. A flurry of activity in the late 1950's preceded Alvis and Novotny's important paper.

Modern Fluorescein Angiography

In early 1959, Chao and Flocks described a method for measuring the retinal circulation time in cats.²⁹ Using a stopwatch, ophthalmoscopy, and tryptan blue, they found that the circulation time of the cat retina was approximately 2 seconds. Their discussion concluded with this observation:

"We do not yet know whether more innocuous indicator solutions such as fluorescein can be used so that the method could be adapted to the human retina. If it could be, it is conceivable that the study of retinal circulation time might be of value in such pathologic conditions as retinitis pigmentosa, diabetic retinopathy, and macular degeneration." Chao and Flocks, 1959

Later that year, Flocks, Miller, and Chao published a refinement of their technique, including the addition of a motion picture camera, an exciter filter, and fluorescein dye:³⁰

"If a cobalt-blue filter is inserted in the ophthalmoscope, the retina appears dark purple in color and the vessels black. When intravenously injected fluorescein reaches the central retinal artery, it lights up the artery to a fluorescent yellow if viewed through the cobalt-blue filter.... The idea was conceived that the end points could be ascertained more precisely by means of motion picture photography using a motion picture film viewer and editor to examine leisurely the individual frames of the film. With this technique the unavoidable error due to the reaction time of the person pressing the stop watch would be eliminated and, in addition, a permanent objective record of the circulation time and of the retinal circulation would be obtained.....

1850	1854 The first color representation of the retina is published.
1860	
1870	1871 Fluorescein is synthesized.
1880	1881 The aqueous flow is examined with sodium fluorescein.
1890	1886-91 In vivo retinal photography of human subjects is attempted and refined.
1900	1899 High quality fundus photographs are shown.
1910	1907 First fundus photography atlas published.
1920	1910 The choroid and retina are examined with sodium fluorescein.
1930	1926 Fundus camera becomes commercially available.
1940	1930 Filters are used to observe dye in the retina.
1950	1939 Dye flowing through retinal blood vessels is described.
1960	1946 The electronic flash tube is invented.
	1953 Electronic flash tube technology is applied to fundus photography.
	1959 Sodium fluorescein is photographed in the cat retina using an exciter filter.
	1960 Sodium fluorescein is used to determine a retinal diagnosis.
	1961 Modern fluorescein angiography technique is described.

Figure 10: timeline relating events which led to the development of the fluorescein angiography procedure.

Their attempts at fundus cinephotography of sodium fluorescein in humans failed:

"Two attempts to determine the retinal circulation times in human beings using motion pictures were unsuccessful because of insufficient light. Motion pictures of the retina of cats is much easier to make than the motion pictures of the human retina. We are currently trying to improve the optical system of our apparatus so that this method can be applied to the study of human retinal circulation time.... "Flocks, Miller, and Chao, 1959

The future of fluorescein angiography was not in determining circulation time, but rather in the evaluation and differential diagnosis of chorio-retinal disease. In 1960, MacLean and Maumenee published this landmark description of fluorescein angiography: the first published case of sodium fluorescein being used to obtain a diagnosis.³¹

"The patient, Stanford University Hospital No E-1234719 J.G., a white man, truck driver, 30 years of age, was first seen in consultation on February 16, 1955. He stated that three years prior to that time he had noted spots and flashes of light in front of his left eye. He had seen an optometrist who prescribed glasses for him. Four weeks prior to his examination visual acuity in his left eye had suddenly decreased... .

A cobalt blue filter was placed in front of the beam of the Haag-Streit slit lamp and the patient was given 2cc of 5.0 percent fluorescein intravenously. A dozen small spots in the central portion of the tumor fluoresced within 30 seconds. A diagnosis of hemangioma of the choroid was made.... " MacLean and Maumenee, 1960

The final piece of our puzzle was to be published in the journal *Circulation* by Novotny and Alvis.¹ The technique used to create the first successful fluorescein angiogram (Fig 9) was published in 1961:

"The purpose of this paper is to describe a method for the study of retinal blood flow in man by the use of intravascular fluorescein and retinal photography, and to report some preliminary observations made with this method.....

Serial fluorescence-photography of the human retinal vasculature provides a dynamic record and increased visibility of the vascular pattern and blood flow by means of a simple technic... .

Separate arteriolar and venous filling phases, an arteriovenous shunt, sluggish choroidal circulation, stratified flow of fluorescein, and rapid central retinal circulation times were observed in normal retinas. Similar findings were seen in hypertensive and diabetic patients, and, in addition, neovascularization was clearly defined, and some cotton-wool patches, but not hemorrhages, were found to fluoresce. "Novotny and Alvis, 1961

Conclusion

Many events preceded the development of the modern fluorescein angiography technique (Fig 10). This paper includes excerpted quotations from the publications of significant contributors. This historical review does not contain every related past event, but summarizes milestones within the process.

The history of fluorescein angiography as a diagnostic test did not stop abruptly at the publication of the last cited paper. This review does not examine the evolution of clinical correlations and the development of the diagnostic effectiveness of the fluorescein angiography test, nor does it examine the rapidly advancing electronic imaging frontier.

History continues to be written as the process is enhanced by new imaging technologies. Previously overlooked papers may acquire significance in light of future developments. Popular techniques of today may wither with the passage of time. A sense of the past prepares us for the future. With an awareness of the past, it is up to us, the ophthalmic photographers of the present, to write the next chapter in the history of fluorescein angiography.

RESOURCES

The reader is encouraged to examine the original texts of the above citations, as well as these books and reviews.

Early Books

- Thorner W. 1903. Die theory des augenspiegels und die photographie des augenhintergrundes. Berlin, Hirschwald
 Dimmer, F. 1907. Ueber die photographie des augenhintesgrundes. Wiesbaden, Bergmann
 Dimmer, F. and Pillat, A. 1927. Atlas photographischer Bilder des Menschlichen Augenhintergrundes. Leipzig, F. Deuticke
 Bedell, A.J. 1929. Atlas of stereoscopic photographs of the fundus oculi. Davis, Philadelphia

Historical Reviews

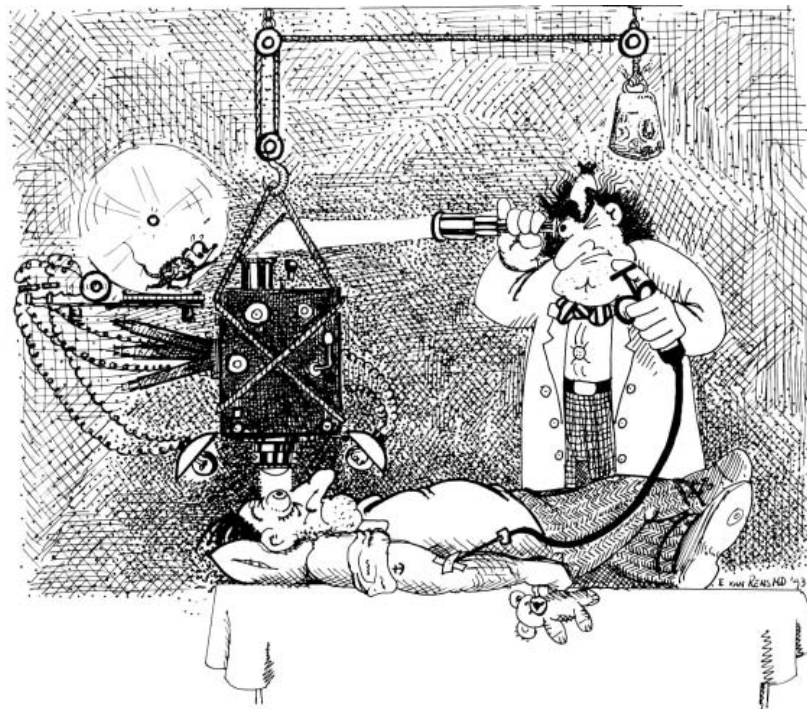
- Alvis, M.D. and Julian, K.G. 1982. The story surrounding fluorescein angiography. *Journal of Ophthalmic Photography*. 5:6-8
 Bedell, A.J. 1935. Stereoscopic fundus photography. *Journal of the American Medical Association*. 105:1502-1505
 Englebert, M. 1965. Uber die photographie des augenhintesgrundes. *Tecnische Roundschau* 39:57
 Hurtes, R. in Justice, J. (editor). 1982. *Ophthalmic Photography*. Boston: Little, Brown, and Co. pg 1-15.
 Liesenfeld, H. 1959. Uberblick uber die entwicklung der augenhintergrundsfotographie. *Ophthalmologica*. 137:390-398
 Mann, W.A. 1970. History of photography of the eye. *Survey of Ophthalmology*. 15:179-189
 Meyer-Schwickerath, G.R.E. 1968. *Ophthalmology and photography*. *American Journal of Ophthalmology*. 66:1011-1019.
 Shatz, H., Burton, T.C., Yannuzzi, L.A., and Rabb, M.F. 1978. *Interpretation of Fundus Fluorescein Angiography*. St. Louis: C.V. Mosby, pg 3-9
 Van Cader, T. C. 1978. History of ophthalmic photography. *Journal of Ophthalmic Photography*. 1:1 pg 7-9
 Wong, D. 1982. *Textbook of Ophthalmic Photography*. New York: Inter-Optics Publications pg 51-52.

REFERENCES

1. Novotny HR, Alvis DL. 1961. A method of photographing fluorescence in circulating blood in the human retina. *Circulation*. 24:82-86.
2. Duke-Elder S. 1961. System of Ophthalmology Volume II, St. Louis: CV Mosby pg 2-3.
3. Duke-Elder S. 1967. System of Ophthalmology Volume X, London: Henry Kimpton pg. 7-16.
4. Jackman WT and Webster JD. 1886. On photographing the retina of the living human eye. *Philadelphia Photographer* 23:275-276.
5. Bedell AJ. 1935. Stereoscopic fundus photography. *JAMA* 105: 1502-1505.
6. Baeyer A. 1871. Ueber eine neue klasse von farbstoffen. *Ber. Dtsch. Chem. Gzellschaft*. 4:555-559.
7. Ehrlich P. 1882. Ueber provocrirte fluoreszenzerscheinungen am auge. *Dtsch. Med. Wochenschr.* 8:21-22.
8. Burke A. 1910. Die klinische, physiologische und pathologische bedeutung der fluoreszenz in auge nach darreichung von uranen. *Klin. Monatsbl. Augenheilkd.* 48:445-454.
9. Kikai K. 1930. Ueber die vitalfarbung des hinteren bulbusschnittes. *Arch. Augenheilkd.* 103:541.
10. Sorsby A. 1939. Vital staining of the retina; preliminary clinical note. *Br. J. Ophthalmol.* 23:20-24.
11. Lange K and Boyd LJ. 1944. The use of fluorescein to determine the adequacy of the circulation. *Med. Clin. North Am.* 943-952.
12. Howe L. 1887. Photography of the interior of the eye. *Trans. Amer. Ophth. Soc.* 23:568-571.
13. Barr E. 1887. On photographing the interior of the human eyeball. *Amer. J. Ophth.* 4:181-183.
14. Gerloff O. 1891. Ueber die photographie des augenhmntergrundes. *Klin. Monat. f. Augenheil.* 29:397-403.
15. Dimmer F. 1907. Ueber die photographie des augenhintergrundes. Wiesbaden: Bergmann pg. 1.
16. Helmholtz H. 1851. Beschreibung eines augenspiegels zur untersuchung der netzhaut in lebenden auge. Berlin: Forstner pg. 1.
17. Thorner W. 1899. A new stationary ophthalmoscope without reflexes. *Amer. J. Ophth.* 16:376-391.
18. Gullstrand A. 1910. Neue methoden der reflexlosen ophthalmoskopie. *Ber. Dtsch. Ophth. Ges.* 36:75.
19. Nordenson JW. 1925. Augenkamera zum stationaren ophthalmoskop von Gullstrand. *Ber. Dtsch. Ophth. Ges.* 45:278.
20. Van Cader TC. 1978. History of ophthalmic photography. *J. Ophth. Photo.* 1:7-9.
21. Ridley H. 1957. Retinal photography. *Trans. Ophth. Soc. U.K.* 77:417-420.
22. Bedell AJ. 1929. Atlas of stereoscopic photographs of the fundus oculi. Davis: Philadelphia pg. 1.
23. Hartinger H. 1936. Emn neue reflexfreie ophthalmoskoplinsle fur die zeiss-nordenonsche netzhautkammer. *Z. Ophthalmol. Optik.* 24:137.
24. Hansell P and Beeson EJG. 1953. Retinal photography in color. *Brit. J. Ophth.* 37:65-69.
25. Cohn P and DuBois-Raymond C. 1888. Photograms of the eye. *JAMA* 10:540.
26. Edgerton HE. 1946. Photographic use of electrical discharge flashtubes. *J. Optical Soc. Am.* 36: 390-399.
27. Rizzutti, AB. 1950. High speed photography of the anterior ocular segment. *Archiv. Ophthal.* 43:365-369.
28. Ogle, KN and Rucker CW. 1953. Fundus photographs in color using a high speed flash tube in the Zeiss retinal camera. *A.M.A. Arch. Ophthal.* 49:435-438.
29. Chao P and Flocks M. 1958. The retinal circulation time. *Amer. J. Ophth.* 46:8-10.
30. Flocks M, Miller J, and Chao P. 1959. Retinal circulation time with the aid of fundus cinematography. *Amer. J. Ophth.* 48:3-6.
31. MacLean, AL and Maumenee AE. 1960. Hemangioma of the choroid. *Amer. J. Ophth.* 50:3-11.

About the author.: Patrick J. Same has been photographing eyes for 12 years and has published several previous papers on ophthalmic photography. He supervises the Ophthalmic Photography Department at Davis Duehr Eye Associates and teaches both ophthalmic and fine art photography. Active in professional organizations, he currently serves as the President of the Ophthalmic Photographers' Society.

Key words: history, fluorescein, fluorescein angiography, photography, fundus photography



Cartoon by Eric Van Rens, MD